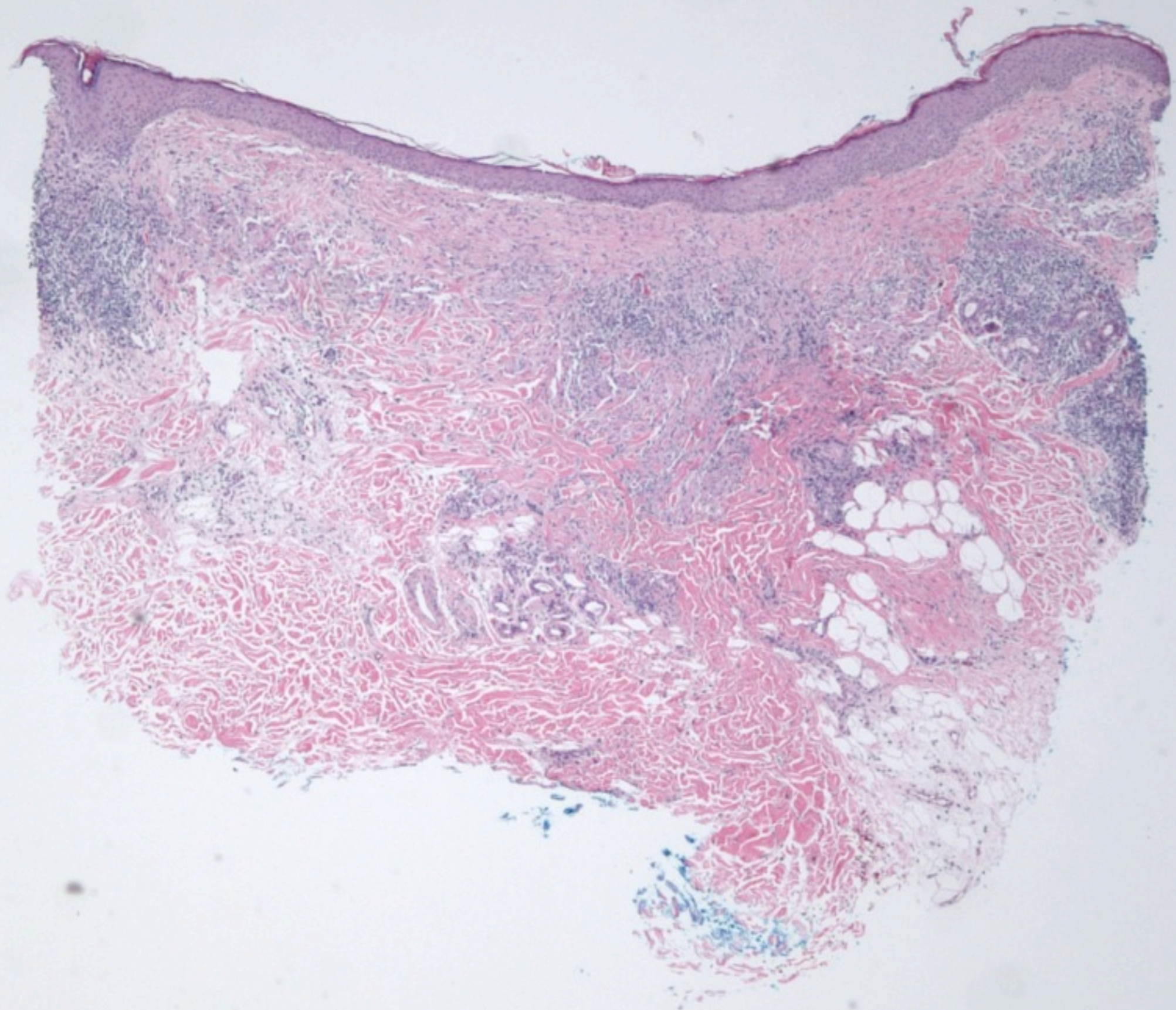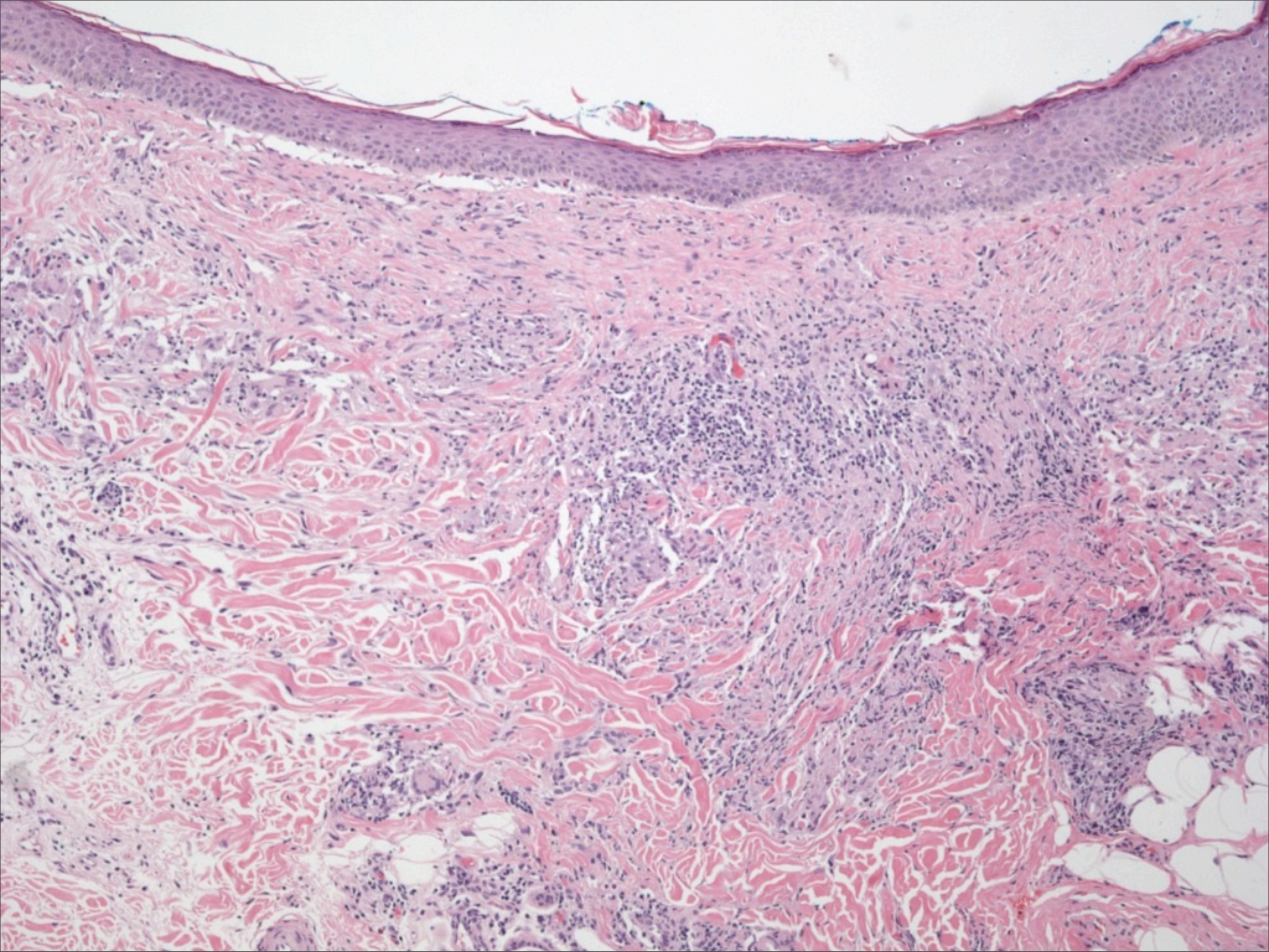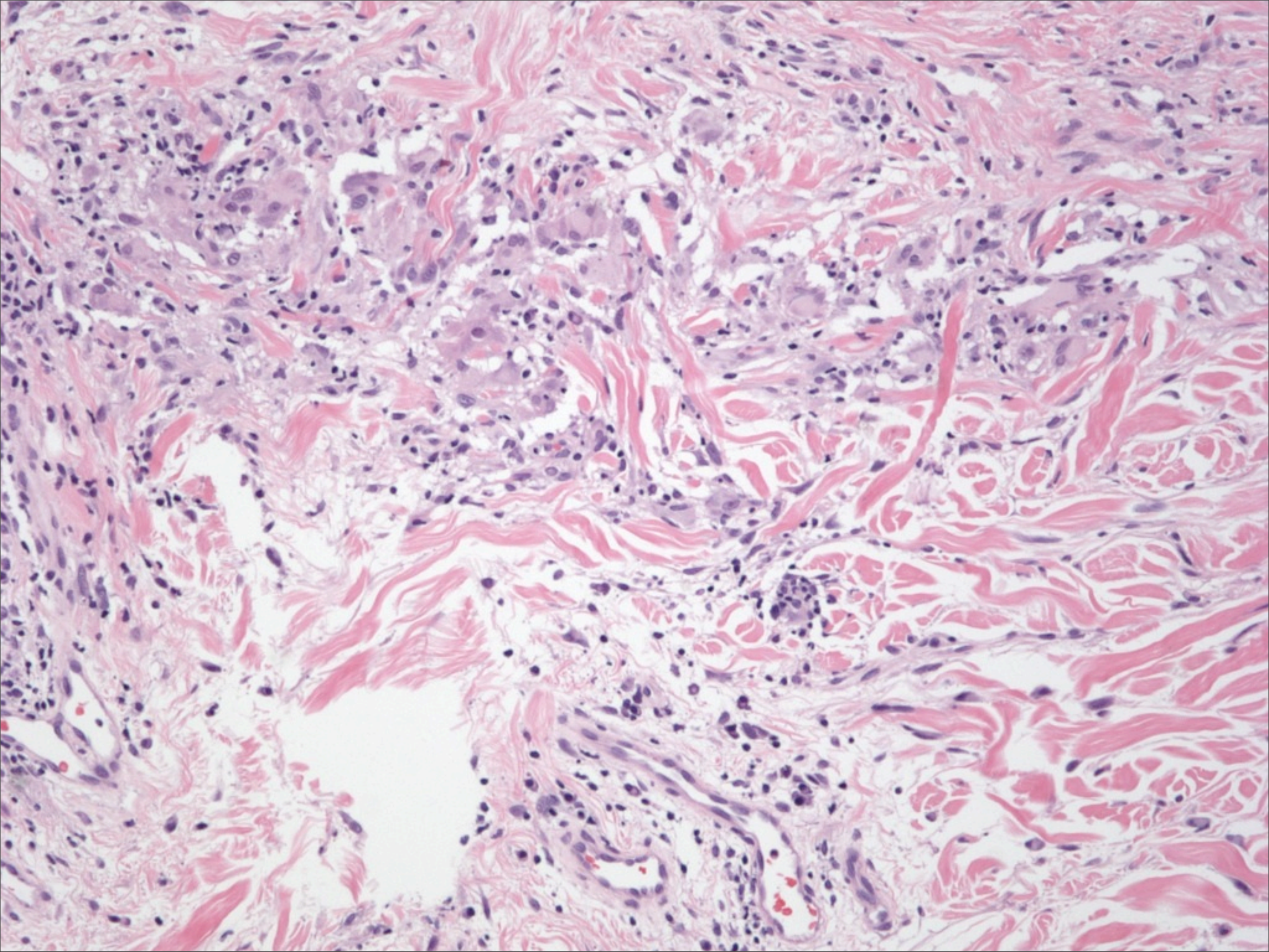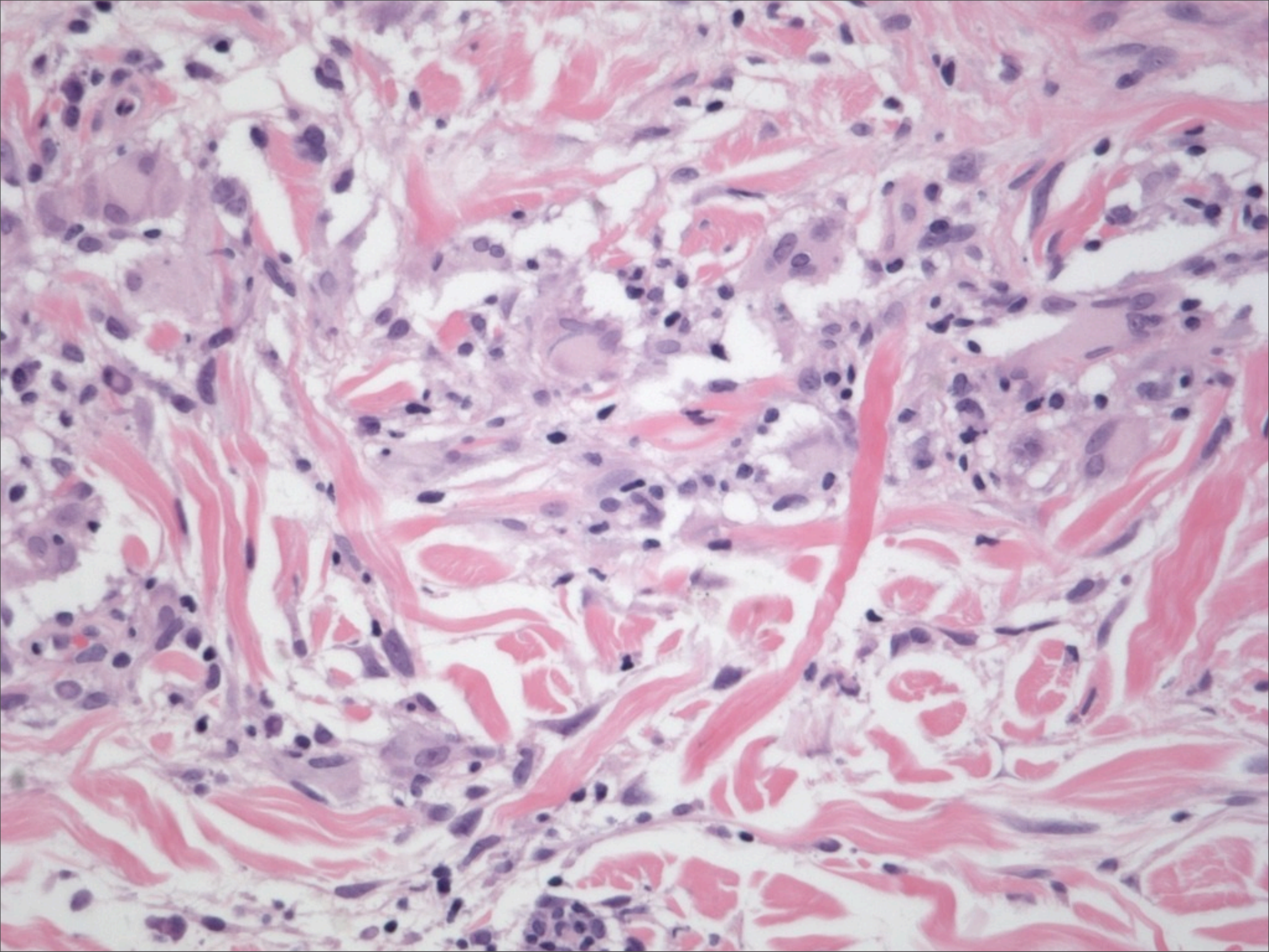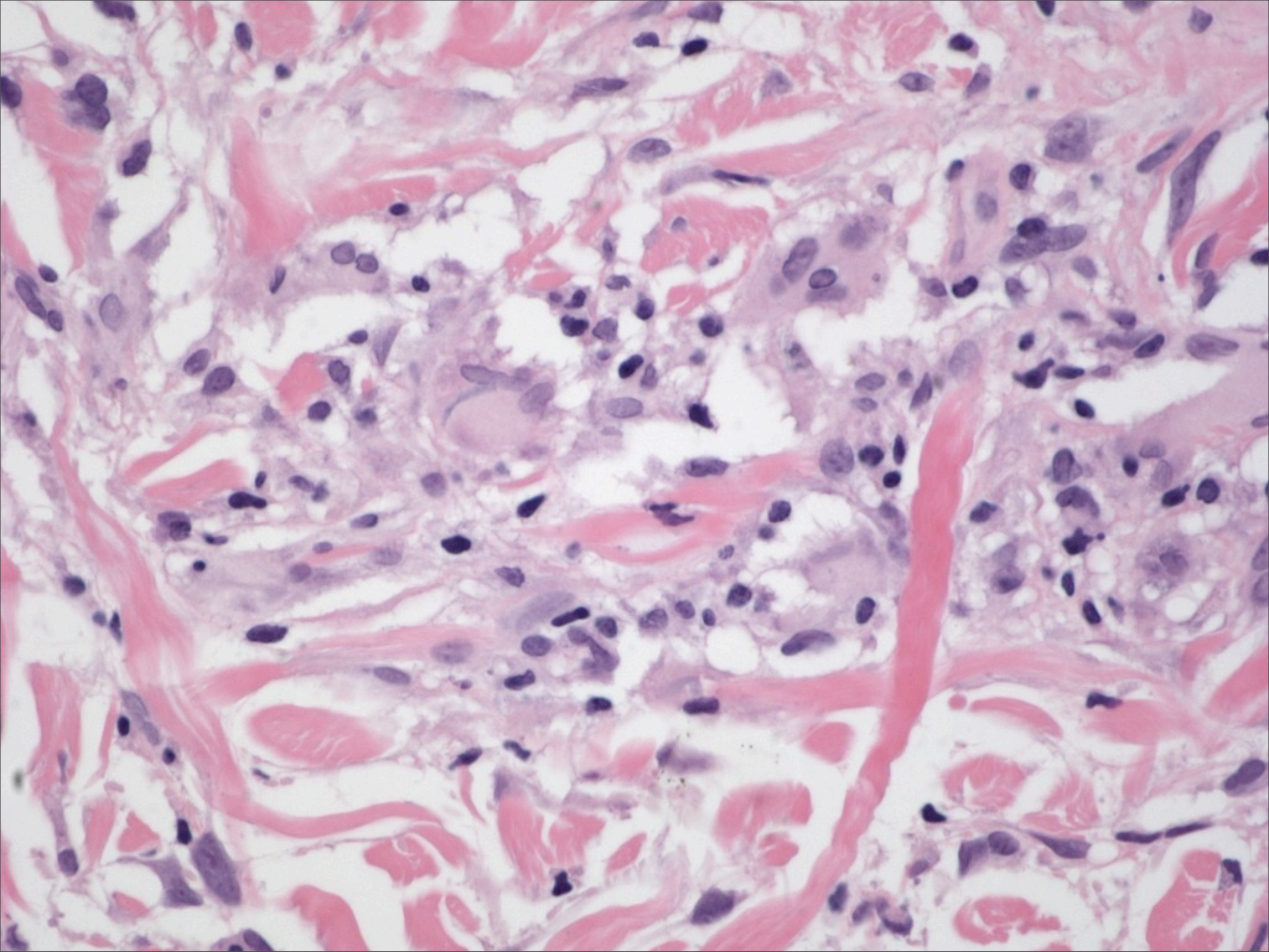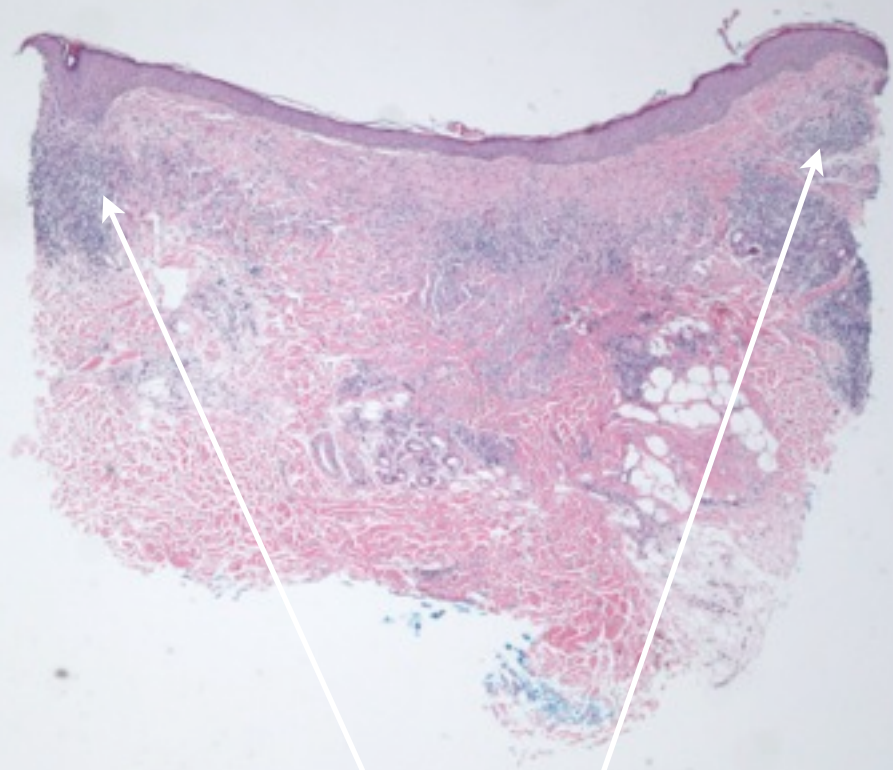
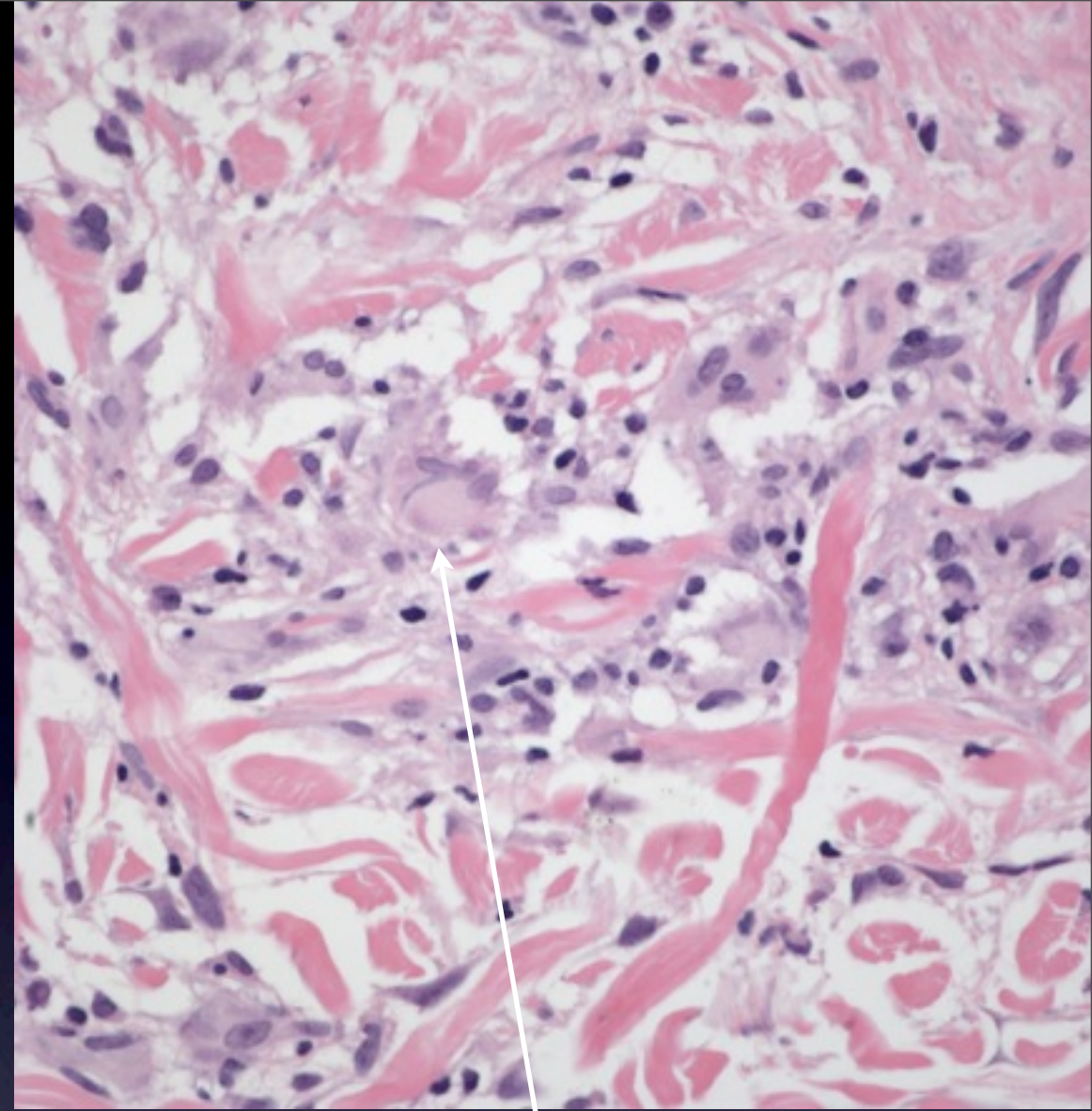


Annular Elastolytic Granuloma (Actinic Granuloma)



Dell-like depression

Cellular infiltrate of
lymphocytes and histiocytes



Giant cells engulfing
elastic fibers